Management of Methicillin-Resistant Staphylococcus Aureus Keratitis in Post-surgical Patients: Two Case Reports

Sujata P. Prabhu, MD and Timothy Y. Chou, MD

Department of Ophthalmology
SUNY at Stony Brook
Stony Brook, New York, USA

The authors have no financial interest in the subject matter of this poster

Purpose

- To describe the clinical course and treatment regimen of two patients with prolonged Methicillin-resistant Staphylococcus aureus (MRSA) keratitis after cataract surgery and penetrating keratoplasty.

Background

- Reports of MRSA-related ocular infections have been increasing in recent years.
- Several case series detail MRSA infections after refractive and cataract surgery[1-5].
- Chiang and Rapuano describe one case and Cosar et al report 2 cases of MRSA-related corneal infection after cataract extraction. The first case resolved after 60 days and time to resolution was 108 days in the second.[4-5]
- No ideal treatment regimen for MRSA-related corneal infections has been determined.

Methods

- The medical records of two patients with MRSA keratitis, one after clear corneal cataract surgery and the other after penetrating keratoplasty, were retrospectively reviewed.
- Data extraction included age, sex, medical history and risk factors for infection, eye culture results and antibiotic sensitivities, and treatment regimen.

Results – Case 1

- 52 year old with male with multiple medical problems including uncontrolled type 1 diabetes for 40 years who underwent cataract extraction of the right eye.
- MRSA keratitis occurred 5 days after cataract extraction associated with endophthalmitis (Figure 1).
- Duration of keratitis was 3 months.

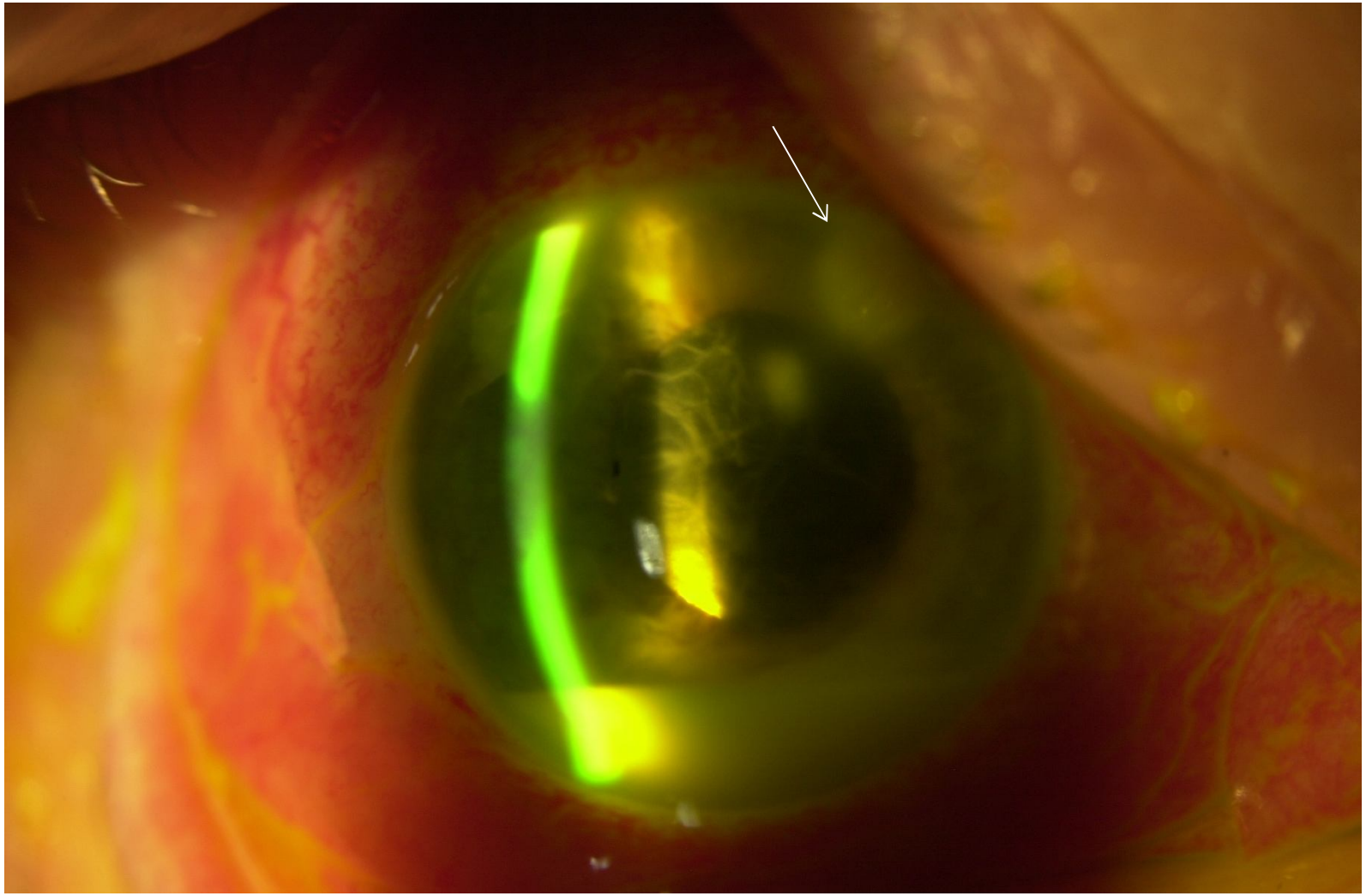

Figure 1. Slit lamp photo on post-operative day 10 showing keratitis and endophthalmitis. Arrow points to infiltrate at paracentesis incision site.

Results – Case 2

- 75 year old white female with multiple myeloma with history of cataract extraction of the right eye complicated by corneal ulcer and endophthalmitis. She later underwent penetrating keratoplasty in the right eye for central corneal scar.
- Diagnosis of MRSA keratitis was made 1.75 years after PK associated with suture abscess (Figure 2).
- Duration of keratitis was 1.5 months.

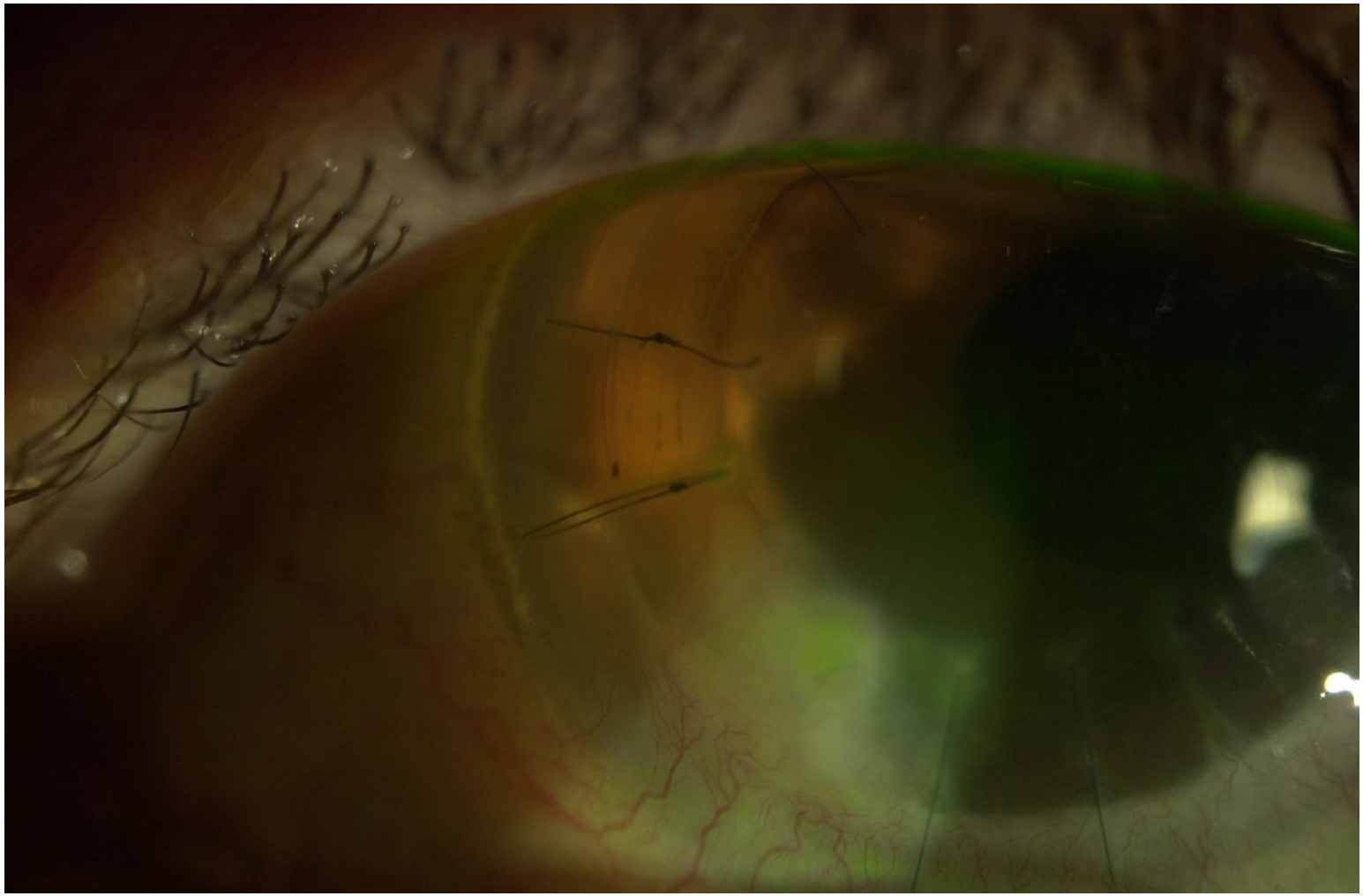

Figure 2. Slit lamp photo showing MRSA infiltrate and ulcer.

Results

- Treatment in both cases included topical fortified vancomycin (50 mg/ml), fortified bacitracin (3000 U/ml), and oral doxycycline to reduce corneal collagenase activity.
- Eradication of MRSA colonization was done with mupirocin ointment applied twice daily to the nares for 5 days and bathing with chlorhexidine gluconate 4% soap.

Conclusion

- We describe the successful treatment of two cases of MRSA keratitis using topical fortified vancomycin, fortified bacitracin, and oral doxycycline.
- Nasal mupirocin and chlorhexidine gluconate 4% soap baths to reduce MRSA colonization may be a useful adjunct to treatment.

Conclusion

- Possible risk factors for infection include an immunocompromised state in both cases due to poorly controlled diabetes mellitus in case 1 and multiple myeloma in case 2.
- MRSA-related keratitis may require prolonged treatment for complete resolution.

References

1. Solomon R, Donnenfeld ED, Perry HD, et al. Methicillin-resistant *Staphylococcus aureus* infectious keratitis following refractive surgery. Am J Ophthalmol 2007; 143: 629–634.
2. Rubinfeld RS, Negvesky GJ. Methicillin-resistant *Staphylococcus aureus* ulcerative keratitis after laser in situ keratomileusis. J Cataract Refract Surg 2001; 27: 1523–1525.
3. Rudd JC, Moshirfar M. Methicillin-resistant *Staphylococcus aureus* keratitis after laser in situ keratomileusis. J Cataract Refract Surg 2001; 27: 471– 473.
4. Chiang R and Rapuano C. Recurrent methicillin-resistant staphylococcus aureus wound ulcer after clear-cornea cataract surgery. The CLAO Journal 2002; 28(3): 109-110.
5. Cosar C, Cohen E, and Rapuano C, et al. Clear corneal wound infection after phacoemulsification. Arch Ophthalmol 2001; 119: 1755-1759.